

Anastomotic dehiscence after proctocolectomy with J-Pouch

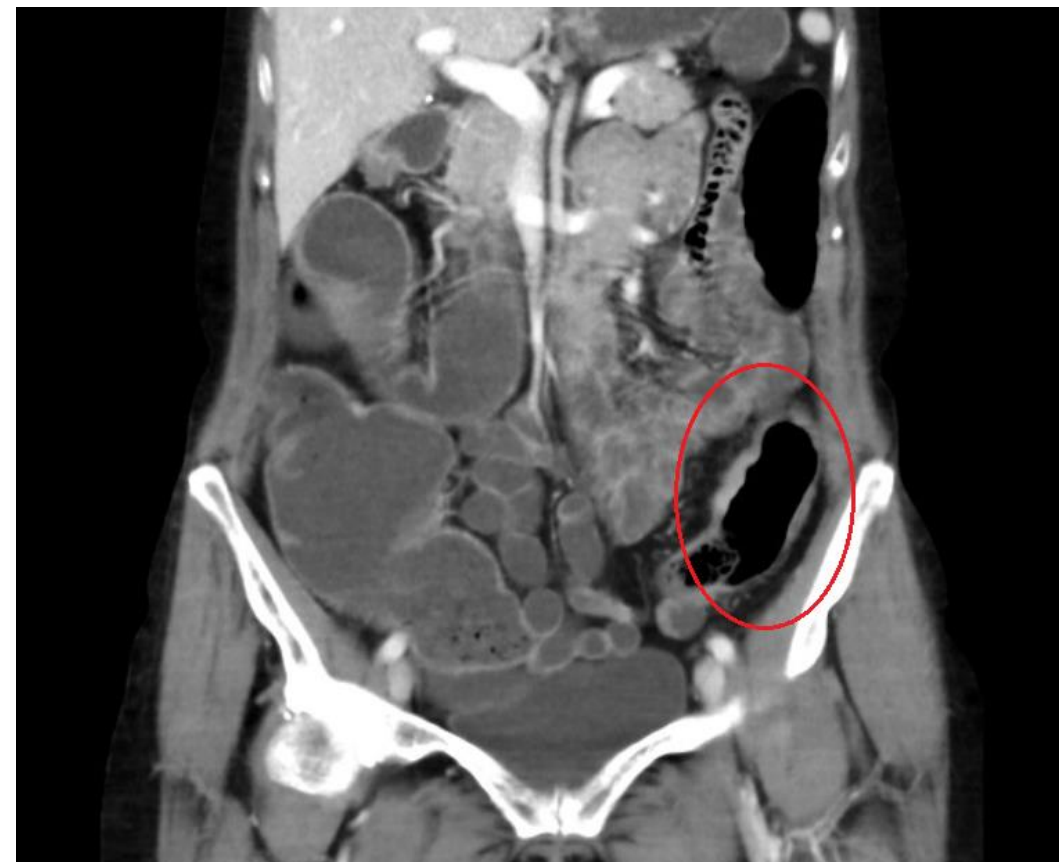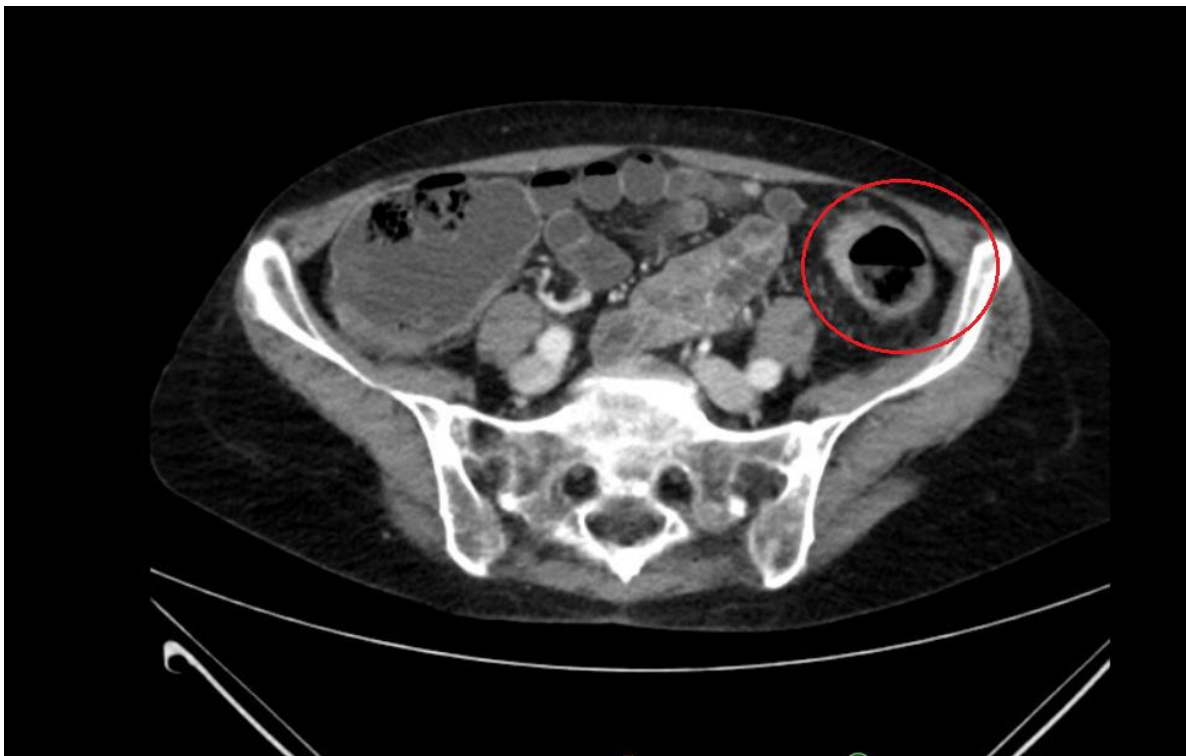
Department of Surgery, University Hospital Brno Bohunice, Faculty of Medicine,
Masaryk University, Czech Republic

Women, 55 years

- BMI 22, ASA 2
- Leiden mutation – heterozygot – st.p. embolia
- Anemia
- st.p. VATS operation for thoracic empyema 2019
- IBD (indetermined colitis) – 35 years

Current illness

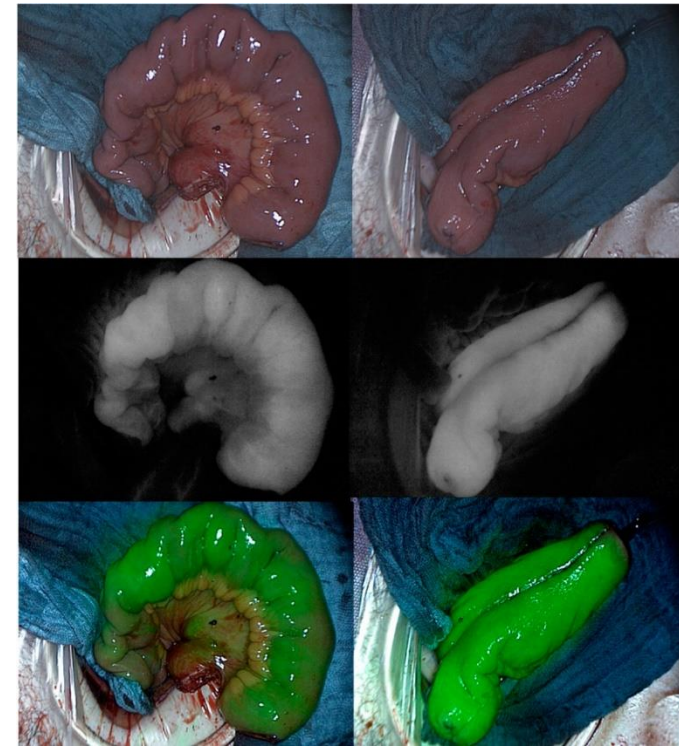
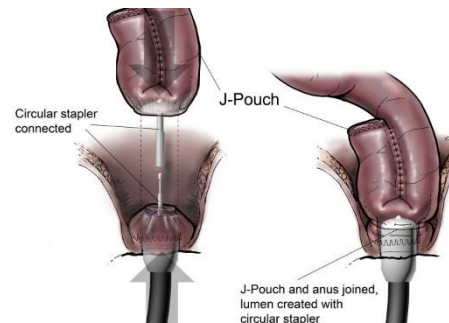
- 35 years - multimodal conservative therapy
- since 2019 – no therapy
- 12/2022 colonoscopy control – in 20cm histologically verified adenocarcinoma G1
- MDT - proctocolectomy with J-pouch and protective ileostomy indicated



Pre - operative CT 12/2022 – focal enhancement of colon descendens

Surgery and postoperative course

- 5.1.2023 proctocolectomy with J-Pouch
- During operation J-Pouch with ischemia – verified by ICG → remade – ICG normal
- stapler IPPA anastomosis S-t-E – stapler 28, protective ileostomy
- postoperative course – no complications
- discharge 7th POD



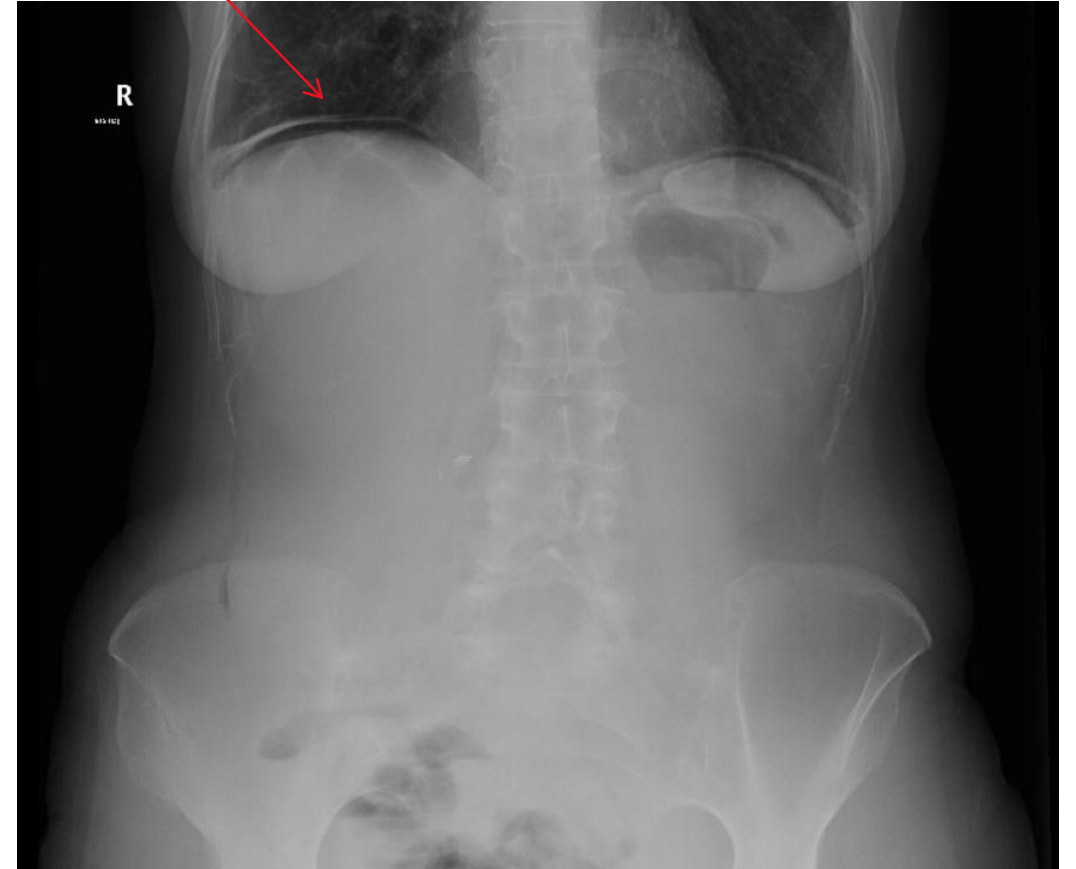
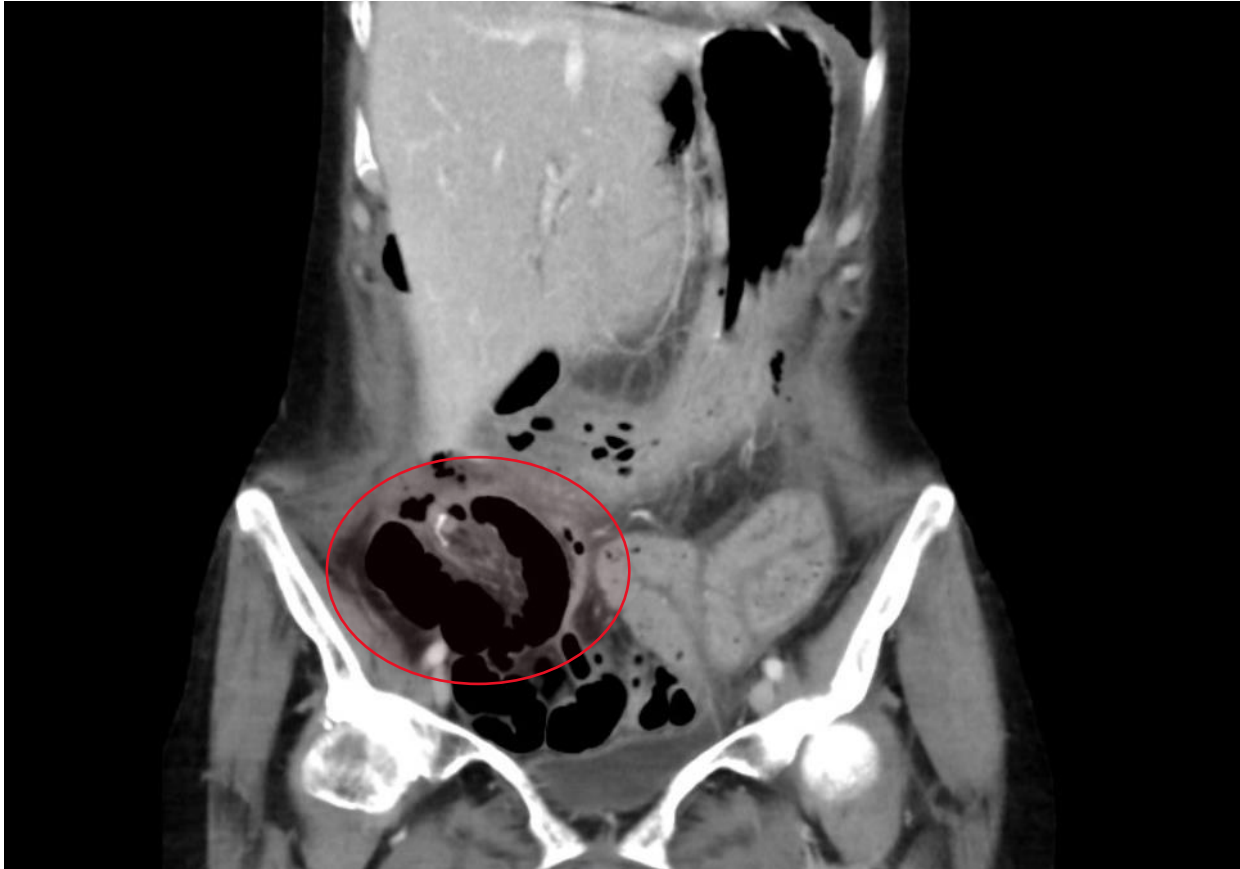Outpatients department

- Definitive histology – adenocarcinoma G1 (pT3 pN0 pM0)
- Oncologic therapy was not indicated – just observation
- 18th POD rehospitalization - dehydration - infusion therapy
- 25th POD pouchoscopy – J-pouch healthy, normotonus of sphincters – ileostomy was indicated

Deileostomy

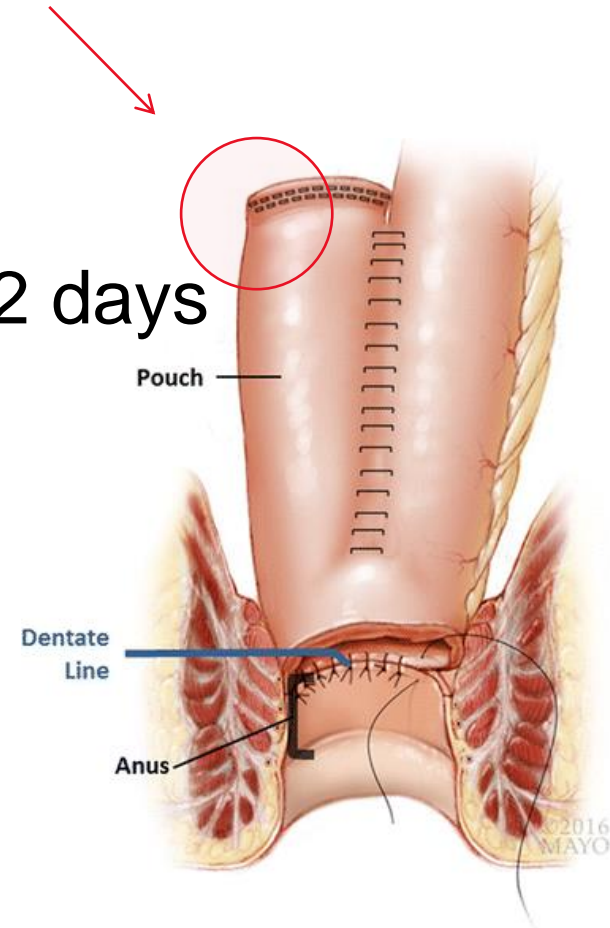
- 45 POD - deileostomy – entero-entero anastomosis side to side
- Postoperative diarrhea, vomiting - conservative therapy
- 6th postoperative day – abdominal pain in low part of abdomen → X-ray → pneumoperitonem
- CT scan – pneumoperitonem and fluid around of entero-entero anastomosis
- Acute operation indicated

Examination



Reoperation

- Complete adhesiolysis
- Entero-entero anastomosis sufficient
- Defect in proximal part of stapler line on J-Pouch (52 days after primary operation)
- Suture of defect and construction of protective axial ileostomy in the primary location



After surgery

- Stoma already after 120cm of intestine – short bowel syndrom.
- Discharge through gastroenterological departement – infusion therapy, realimentation and home parenteral therapy which is now in progress.
- 6/2023 – pouchoscopy – pouch healthy
- surgical Check-up – deileostomy not indicated
- Oncological observation – no therapy