

Surgery Collaborative and Long-term Practical Experience Learning

SCaLPEL

Case report

Branko Bogdanić, MD, PhD

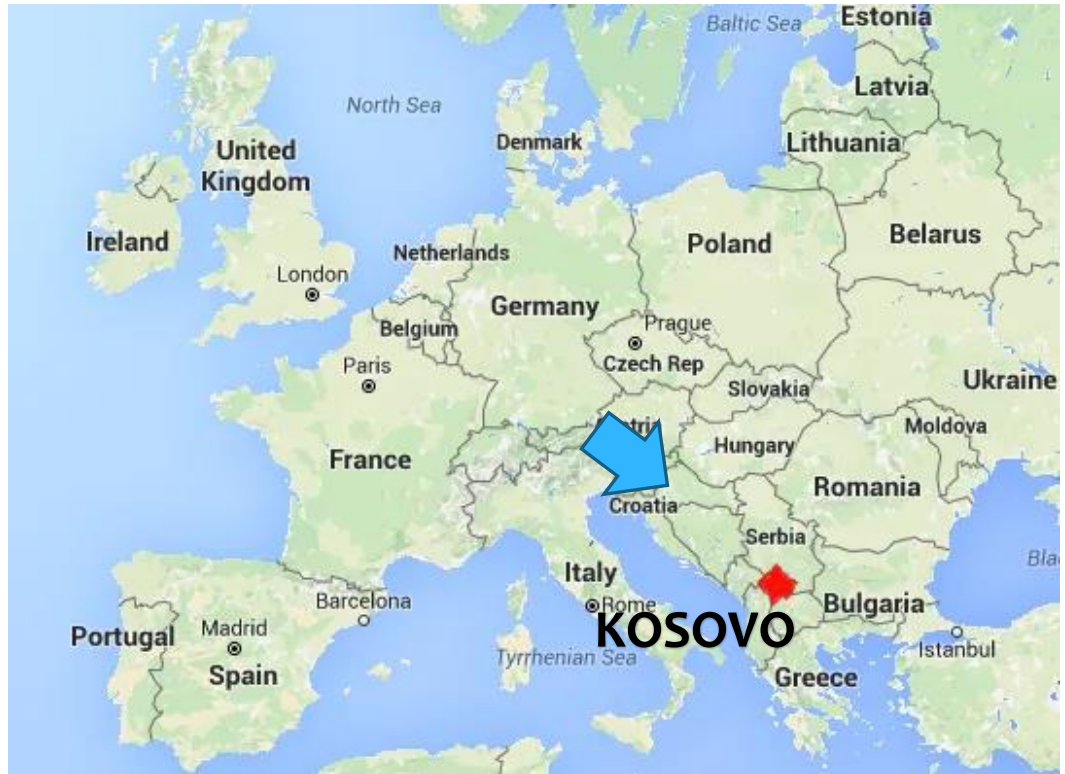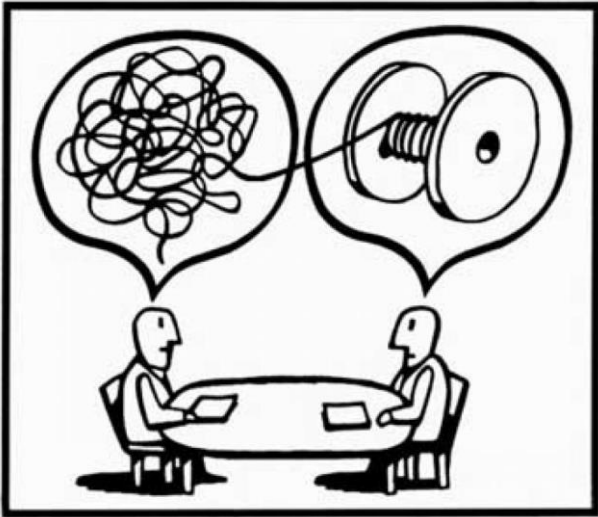


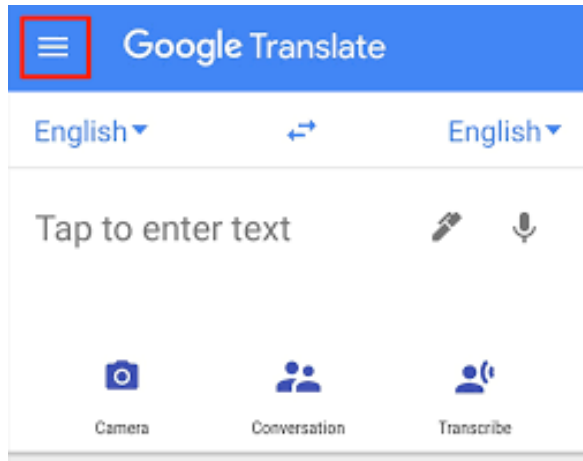
**Co-funded by
the European Union**



- * Female
- * Age 57
- * BMI = 44.9 kg/m²

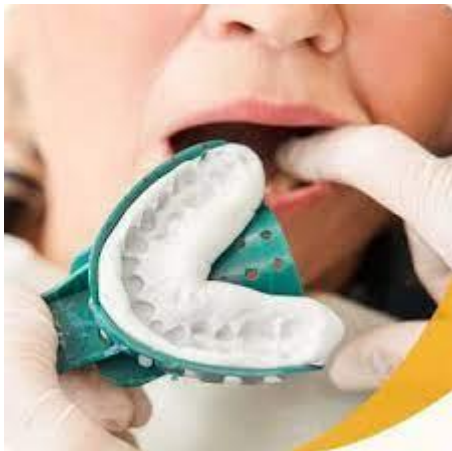






Anamnesis:

- Arterial hypertension
- Appendectomy (1976)
- Cesarean section (1995)



Medications:

Roswera a 20mg, Ampril a 5mg/25mg,
Verapamil a 240mg, Pantoprazole a 40mg

- 
- * RR 137/72mmHg, c/p 117/min, sO₂ 97%, Ttemp 38.8°C
 - * Abdomen: soft, elastic walls, painful on palpation on the right, positive Murphy's sign, without defenses and irritation of the peritoneum, without organomegaly, audible peristalsis. LS right positive

LAB:

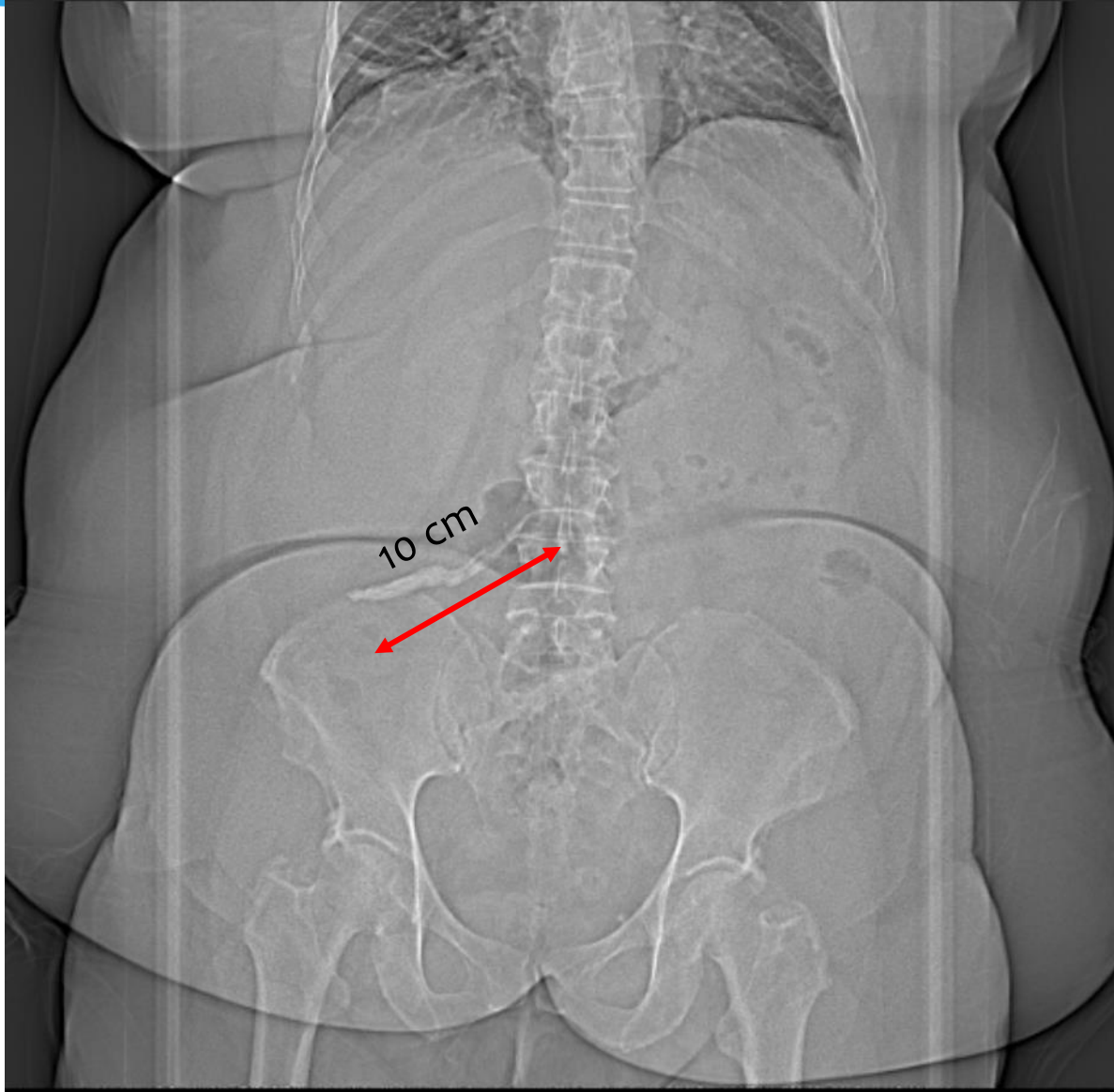
Erc=4.23 Hb=126 Htc=0.365

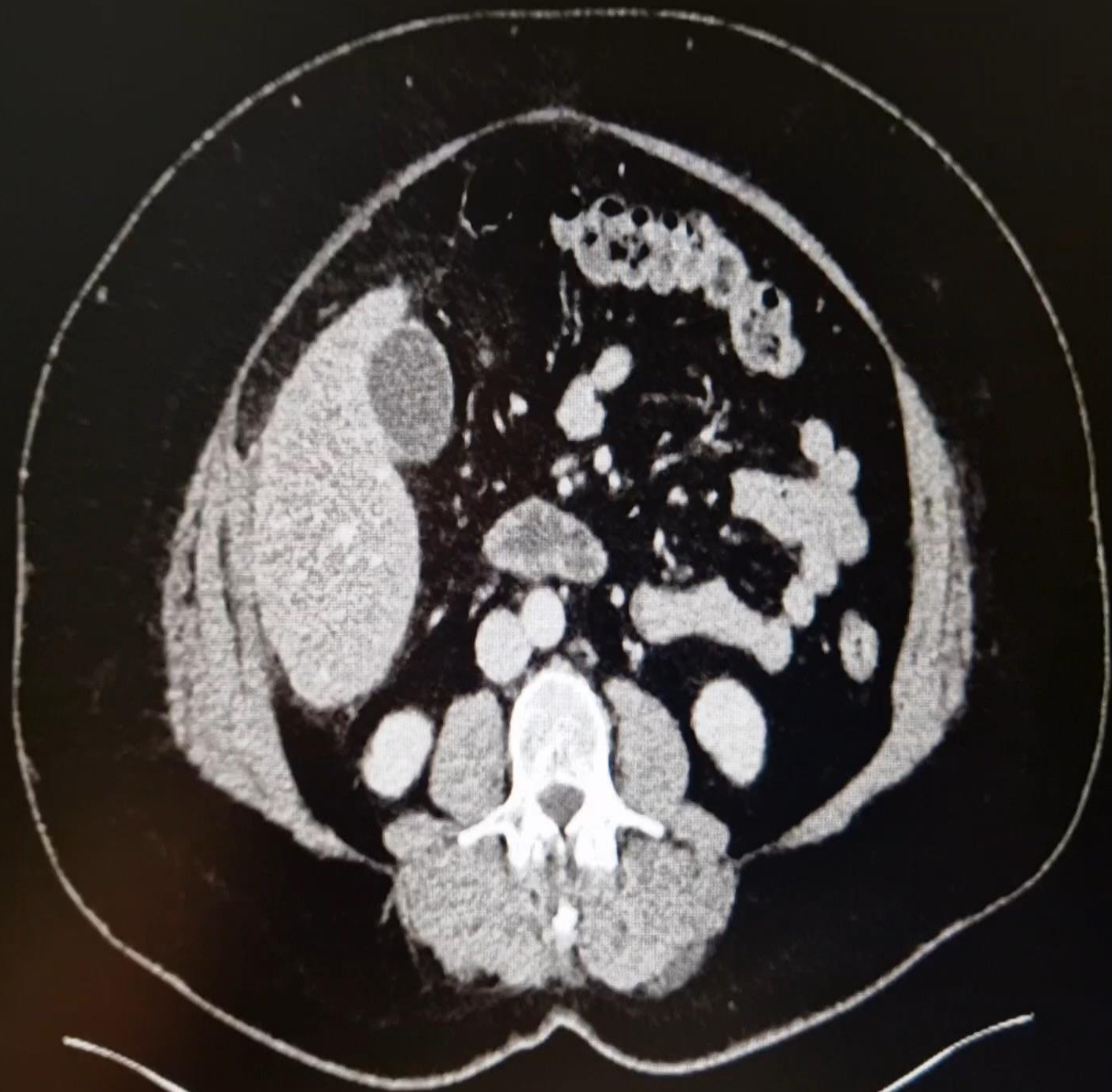L=17.2

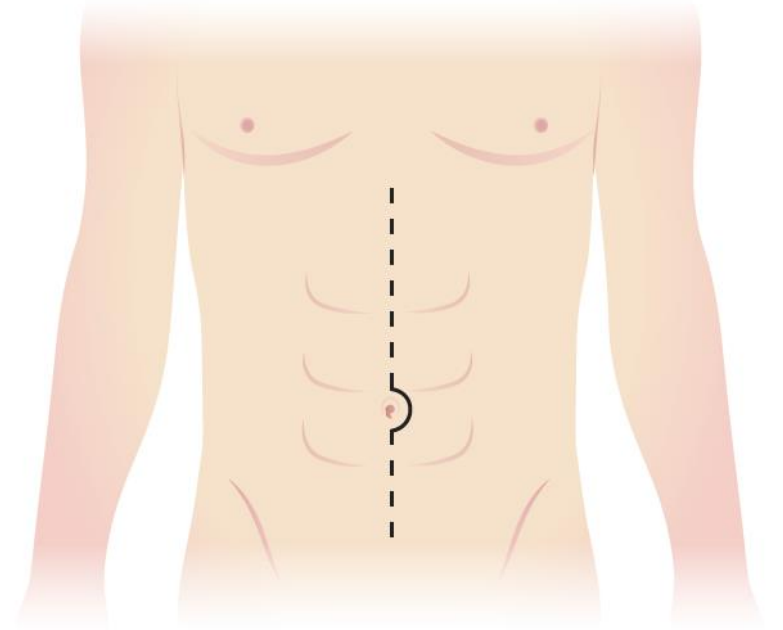
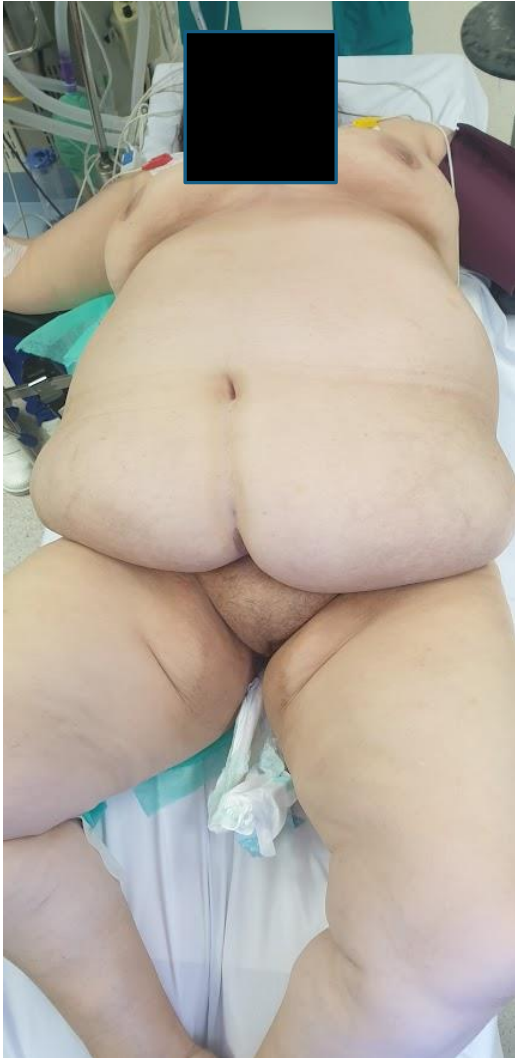Trc=169

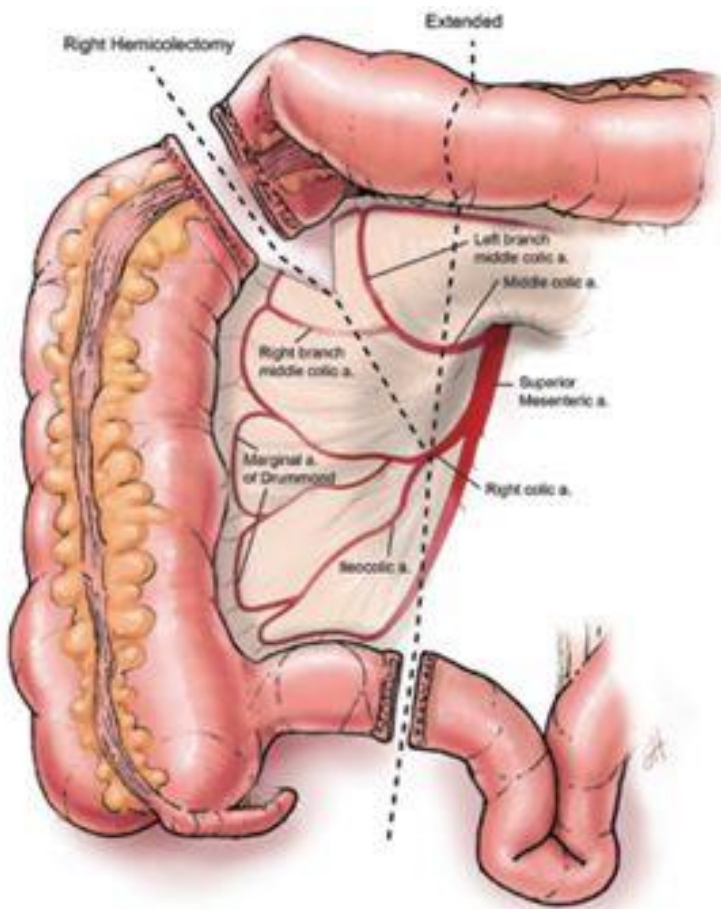
CRP=222.5

CoV-2 Ag=negativan[//]



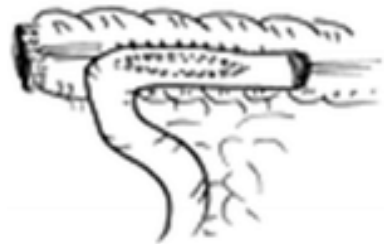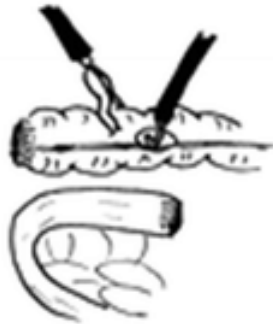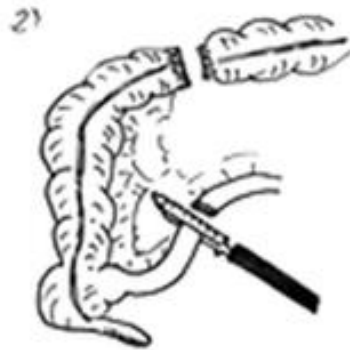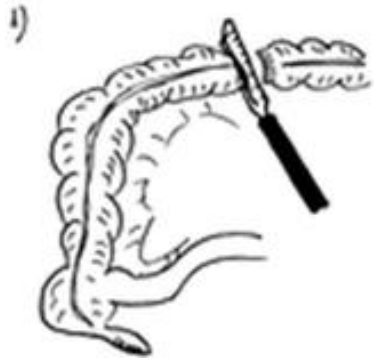





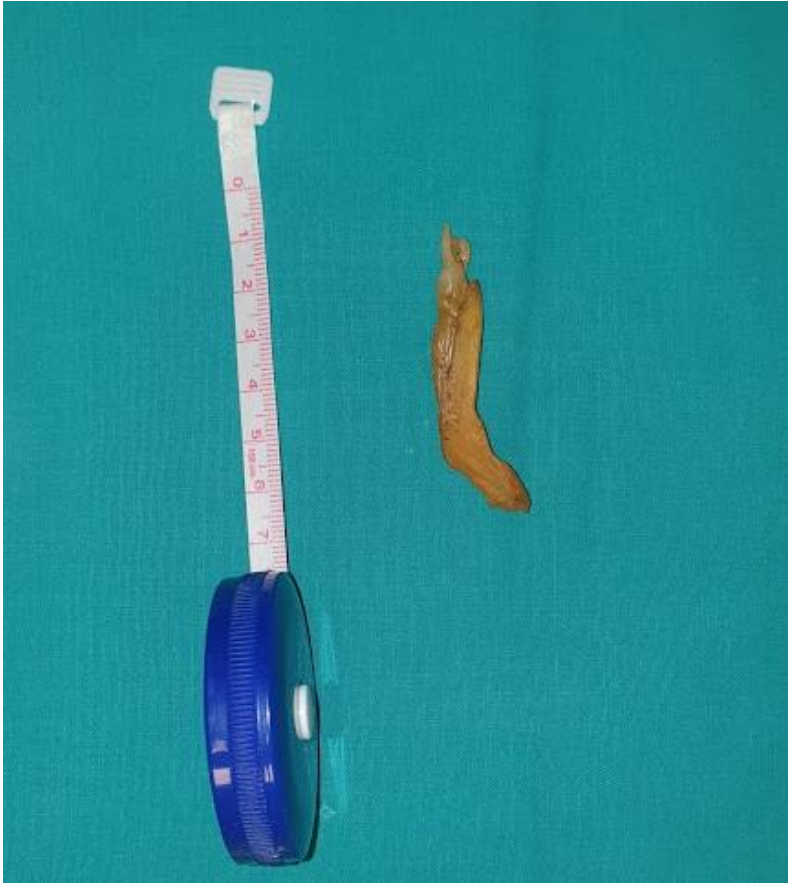
Duodeno-ascending fistula








Postoperative course

* Superficial SSI





ATTENTION, ATTENTION!!